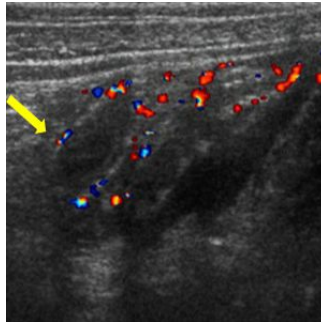

Ultrasound Diagnoses Appendicitis



Children suspected of having appendicitis are more likely to receive CT scans, which involve radiation, if they are evaluated at a general hospital, a new study by Washington University School of Medicine in St. Louis, USA, has shown. Similar patients who went to St. Louis Children's Hospital were more often evaluated with an ultrasound scan, a safer option.

Use of either scanning technique can potentially reduce the occurrence of unnecessary surgeries and expedite the diagnosis of appendicitis. But recent reports have suggested that the radiation exposures in CT scans can significantly increase children's lifetime cancer risk. As a result, researchers are reassessing the role of CT scans and seeking ways to reduce their use.

"Appendicitis is a very tough diagnosis, because its symptoms overlap with viral infections and other problems," said Jacqueline Saito, MD, assistant professor of surgery. "We don't want to operate when the appendix is fine, but if we wait too long, an inflamed appendix can rupture or perforate, making recovery more complicated and much slower."

Saito and her colleagues analysed case records of 423 children who had appendectomies at St. Louis Children's Hospital. In 218 patients initially evaluated at Children's Hospital and 205 at general hospitals, researchers reviewed how the patients were evaluated for appendicitis and whether the surgery's results confirmed the diagnosis.

CT scans, which take X-ray images from multiple angles, have been the primary diagnostic scan for detecting appendicitis for many years. About 85 percent of children initially evaluated at a general hospital underwent preoperative CT scans, and 45 percent of children initially seen at St. Louis Children's Hospital had CT scans. Using ultrasound to detect appendicitis has recently become more frequent, especially at St. Louis Children's Hospital; over half of children initially seen at St. Louis Children's Hospital, compared to 20 percent at general hospitals, had preoperative ultrasound. Only 7 percent were not scanned using either method, and 15 percent had both types of imaging.

While ultrasound scans are safer for diagnosing appendicitis in children, they must be performed and interpreted by personnel who have received specialised training and are familiar with paediatric diagnostics.

"Ultrasound scans are difficult to perform correctly in this context, and what specialists can do at Children's Hospital may not be realistic or even available in a general hospital, which doesn't care for children as often," Saito says.

Saito is currently studying the outcomes of patients whose scans ruled out an appendectomy, looking to see if they had any additional symptoms or eventually had to have their appendixes removed.

"Ultimately what we'd liked to do is learn how we can reduce our use of CT imaging without compromising patient care," she says. "We want to find ways to identify the patients who really need these scans and those who can be effectively evaluated using other methods."

The study is available online in the journal *Pediatrics*.

IMAGE CAPTION Coloured areas on the appendix (whose tip is marked by the yellow arrow) indicate increased blood flow, a sign of the inflammation that characterises appendicitis. This data helps doctors decide if surgery to remove the appendix is necessary.

Published on : Tue, 8 Jan 2013