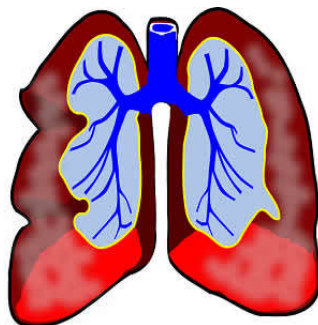


---

## The Imaging of Small Pulmonary Nodules



---

Lung cancer is the leading cause of cancer death worldwide. New developments in radiographic techniques as well as endobronchial ultrasound (EBUS) techniques have generated increased interest in lung cancer screening, according to a review paper published in the journal *Translational Lung Cancer Research*.

**See Also:** [Lung-RADS: Potential Drawbacks and Need for Revision](#)

Nearly 70% of patients with lung cancer present with locally advanced or metastatic disease at the time of diagnosis. Screening of early lung cancer has been a continuing issue over the last 40 years.

Small lung nodule is a common problem in pulmonary practice. Possible causes of pulmonary nodules include many benign diseases, but the primary concern is bronchogenic carcinoma. Large tumour size and advanced stage are associated with worse prognosis. Faced with a small pulmonary nodule, the radiologists must first assess the likelihood of lung cancer utilising a range of parameters that includes age, nodule size, smoking history, the number of nodules, the presence of radiographic or clinical signs of inflammatory lung disease, and the density of the nodule.

### Computed Tomography (CT)

In 2000s, multi-detector row CT was used in screening programmes, reducing the radiologist's workload. A CT exam can scan the entire thorax to acquire thin-section images in less than 10 seconds. Depending on the screening, the radiologist can get multiple spiral data during a single CT screening that helps them to generate clear CT images of different section thickness, even with very small lung nodules. Computer-aided detection (CAD) methods that are applied to CT examinations also help radiologists in reviewing large sets of image data.

### PET/CT

Positron emission tomography (PET) is the most important advance in lung cancer imaging since the use of CT scanning, the authors say. The emergence of combined PET/CT imaging has greatly aided the investigation of lung cancer. In a retrospective study on identification of characteristics of solitary pulmonary nodule, the sensitivities of CT, PET and PET/CT were 93%, 69% and 97% respectively, while specificities were 31%, 85% and 85%.

A previous study, however, has shown that malignant nodules less than 1 cm were hard to image using PET. The spatial resolution of current generation of PET scanners is 7–8 mm, which can hardly image pulmonary nodules <1 cm.

### Endobronchial Ultrasound (EBUS)

The endobronchial application of ultrasound for the diagnosis of lung cancer was first described in 1992. Since then, major technological advances have occurred and much published research was reported on the indication and diagnostic accuracy of EBUS. Nowadays, EBUS has emerged as a highly effective and minimally invasive technique for sampling peribronchial, mediastinal, and lung masses for pathologic examination.

EBUS plays a role in the staging of non-small cell lung cancer (NSCLC) and the diagnostic evaluation of endobronchial lesions, peripheral pulmonary nodules (PPNs), and mediastinal abnormalities. Some studies using EBUS for mediastinal staging showed strong sensitivity and specificity.

### Conclusion

There have been great advances in image processing allowing for both characterisation and detection of small pulmonary nodules, but the early diagnosis of lung cancer is still very hard. Crucial breakthrough is still needed. Combining several detection methods may lead to technological improvement.

Source: [Translational Lung Cancer Research](#)

Image Credit: Pixabay

