

SNMMI Image of the Year: PET and Optical Imaging

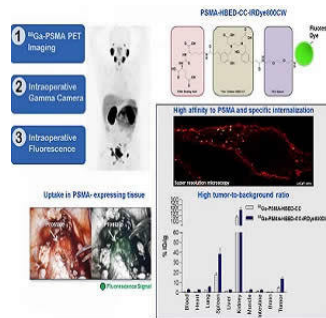


Image-guided surgery for the removal of lymph node metastases can have a significant impact on outcomes in patients with metastatic prostate cancer. The research was presented at the 2017 Annual Meeting of the Society of Nuclear Medicine and Molecular Imaging (SNMMI).

Researchers demonstrated that dual-labeled PSMA-inhibitors based on PSMA-11 enhance preoperative staging, using PET/CT followed by fluorescence-guided surgery. This approach was more successful in accurately detecting PSMA-positive tumour lesions.

Each year, the SNMMI selects an image that exemplifies the most promising advances in nuclear medicine and molecular imaging. This year, the award goes to a team of researchers from the German Cancer Research Center (DFKZ) and University Hospital in Heidelberg. The image demonstrates the advantages of combining Ga-PSMA PET and intraoperative gamma and fluorescence imaging for improved tumour identification before and during surgery. The image was selected from more than 2000 abstracts that were voted on by reviewers and society leadership.

"We are deeply honoured to receive this award, and I would like to thank all team members who contributed to this interdisciplinary work," said Ann-Christin Baranski. "As resection of lymph node metastases has considerable impact on the outcome of metastatic prostate cancer patients, the aim of our study is to improve the intraoperative accuracy of detecting PSMA-positive tumour lesions."

Satoshi Minoshima, MD, PhD, chair of the SNMMI Scientific Program Committee and SNMMI vice president-elect said that the study presented by the researchers demonstrated the advantages of combined PET imaging, gamma detection, and optical imaging during the pre-operative stage and for intra-operative guidance of metastatic lymph node dissection. These hybrid cancer detection methods will be used more frequently in the future and are expected to improve the care and management of prostate cancer patients.

Source: [Society of Nuclear Medicine](#)

Image Credit: Courtesy of A. Baranski, M. Schäfer, U. Bauder-Wüst, M. Roscher, J. Schmidt, E. Stenau, L. Maier-Hein, M. Eder, K. Kopka, German Cancer Research Center, Heidelberg, Germany; T. Simeonova, B. Hadaschik, U. Haberkorn, Heidelberg University Hospital, Heidelberg, Germany; PET-image: Afshar-Oromieh et al., EJNMMI 2013; 40(4); STED-image: J. Matthias, German Cancer Research Center.

Published on : Sat, 17 Jun 2017