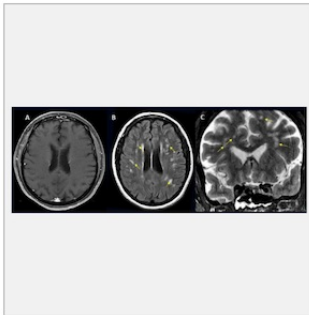

#RSNA21: Spectrum of COVID-19 Brain Complications



Findings from a large international study on brain complications of COVID-19 were presented at the annual meeting of the Radiological Society of North America in Chicago.

Study findings show that approximately one in 100 patients hospitalised with COVID-19 will develop complications of the central nervous system. These complications can include stroke, haemorrhage and other potentially fatal conditions.

Study authors point out that pulmonary complications related to COVID-19 have been discussed quite frequently since the pandemic started but very little has been said about other organs of the body that could be affected by the coronavirus. This study shows that central nervous complications from COVID-19 are a significant cause of morbidity and mortality in patients who develop severe illness.

Nearly 40,000 COVID-19 positive patients from seven U.S. hospitals and four European university hospitals were included in the study. The average age of the study participants was 66 years.

The most common reasons for hospital admission were confusion and altered mental status, followed by fever. Many of the patients included in the analysis suffered from comorbidities, including hypertension, diabetes and cardiac disease.

As per the findings of the study, the incidence of central nervous system complications in the study participants was 1.2%. This translates into one in 100 patients with COVID-19 who will have a brain problem of some sort. A total of 442 acute neuroimaging findings were found to be associated with COVID-19. Among reported complications were ischaemic stroke, intracranial haemorrhage and encephalitis. A very small percentage of patients also reported acute disseminating encephalomyelitis and posterior reversible encephalopathy syndrome.

Overall, findings show an overall incidence of CNS complications in COVID-19 positive patients to be 1.2%. Patients who underwent neuroimaging had ~10% incidence of CNS complications.

Source: [RSNA](#)

Image Credit: RSNA

Published on : Tue, 30 Nov 2021