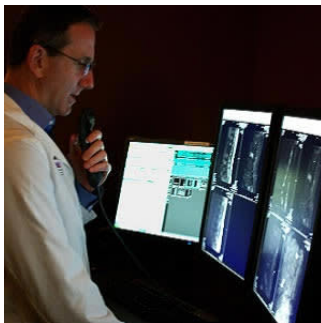


---

## Radiologists do not routinely report gadolinium deposition findings



---

### Radiologists do not routinely report gadolinium deposition findings

Brain deposition of gadolinium following the administration of gadolinium-based contrast agents (GBCAs) was initially reported in 2014, although its potential clinical implications remain unclear. Researchers have conducted an international survey of radiologists to determine their reporting practices in response to gadolinium (GD) deposition. The study reveals high variability regarding radiologists' recognition and reporting of brain GD deposition.

"Recognition of, and attitudes toward, brain gadolinium deposition were inconsistent in this worldwide sample. Most surveyed radiologists do not routinely report dentate T1 shortening as a marker of gadolinium deposition. Fear of provoking patient/clinician anxiety and an incomplete understanding of the implications of gadolinium deposition contribute to inconsistencies in reporting," according to the study published online in the journal *Current Problems in Diagnostic Radiology*.

In 2014 Kanda et al. and Errante et al. first attributed dentate T1 shortening to GBCA exposure. Subsequent work including autopsy studies has confirmed brain GD deposition even in patients with normal renal function. Although the link between T1 shortening in specific brain regions and cumulative exposure to certain GBCAs has been established, the clinical significance of intracranial GD accumulation, if any, remains unknown.

Researchers conducted an online survey of radiologists using SurveyMonkey.com over 17 days spanning November-December 2015. A 10-question survey was distributed by study authors through Radiopaedia.org using social media including Facebook and Twitter. The study sample included 94 total respondents (50% academic; 27% private practice; 23% hybrid) from 30 different countries (USA 18%). Key findings include:

- 57 radiologists (62%) had observed brain GD deposition on MRI brain studies, however, more than half of these (30 of 57) reported detecting dentate T1 shortening only rarely (<1/month).
- Among respondents, 58% (52 of 89) do not or would not include the finding in the radiology report; only 12 (13%) report the finding in the impression of their reports.
- The most common reason for not reporting GD deposition was the risk of provoking unnecessary patient anxiety (29%, 20 of 70).
- Recent data on GD deposition has led to a reported practice change in 24 of 87 (28%) of respondents.

"Although evidence now clearly attributes dentate T1 shortening to cumulative exposure to GBCAs, this is a relatively recent discovery that may not be widely disseminated throughout the medical and radiologic communities," the study authors write.

The authors also note that referral patterns and patient populations of individual practices vary and such differences will impact the incidence of GD deposition. For instance, radiologists practising at a tertiary care centre with a large population of patients undergoing annual surveillance for multiple sclerosis are much more likely to encounter patients with high cumulative dose exposure than radiologists in a rural community setting.

"Time will tell whether or not GD deposition represents a real risk to our patients. Until we know whether intracranial GD reposition has negative health consequences, radiologists must be cognizant of the way in which we report the imaging manifestations of GD deposition in the brain and consider the potential impact of what we report on our patients, referring physicians, and ourselves," the authors conclude.

Source: [Current Problems in Diagnostic Radiology](#)

Image Credit: [User:Zackstarr](#)

Published on : Tue, 20 Mar 2018