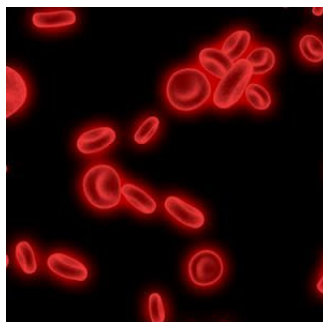


## PSP for Early Diagnosis of Post-Operative Peritonitis, Intra-abdominal Infection, Sepsis




Intra-abdominal infections, postoperative peritonitis, sepsis, septic shock and multiple organ failure have high mortality in the ICU (at nearly 30%) and require complex management and multiple surgical interventions.

The following case report demonstrates the use of serial pancreatic stone protein (PSP) measurements, a biomarker of infection and sepsis that could aid the diagnosis of recurrent intra-abdominal infection and postoperative peritonitis.

A 62-year-old man with no medical history was admitted for elective radical prostatectomy by robotic laparoscopy. The surgery was successful without immediate complications. However, on postoperative day 4, the patient complained of severe abdominal pain. He also had high inflammation and infection biomarker levels - C-reactive protein CRP > 400 mg/l and PSP > 600 ng/ml. An abdominal CT scan showed free intraperitoneal fluid. The patient underwent emergency laparoscopy and middle laparotomy for diffuse purulent postoperative peritonitis. Two ileal perforations were diagnosed. A distal ileostomy was performed on the first perforation and an anastomotic resection on the second. The patient was then transferred to the ICU. He had severe septic shock and multiorgan failure with acute kidney injury.

The patient was started on antibiotic therapy. *Staphylococcus aureus* and *Streptococcus anginosus* were detected in the peritoneal fluid cultures 48 hours later.



Postoperative day 7, the patient underwent intraperitoneal lavage and drainage, and a wall vacuum-assisted closure VAC was implemented. He was put on antimicrobial therapy for seven days. He required renal replacement therapy until postoperative day 10 and mechanical ventilation and catecholamine support till day 12. The patient had no fever or abdominal pain on days 13 and 14. On day 14, his PSP was measured on the point-of-care abioSCOPE® device (Abionic SA, Epalinges, Vaud, Switzerland) and was determined to be 387 ng/ml. Due to the high concentration of PSP, he underwent an abdominal CT scan that showed free fluid and no sign of ileus, perforation or anastomosis release. He was rescheduled for surgery, and the laparotomy revealed a loosening of the ileal anastomosis and the presence of postoperative peritonitis. Another distal ileostomy was performed with abundant peritoneal lavage and abdominal wall VAC. *Escherichia coli*, *Enterococcus faecalis* and *S. aureus* were detected 48 hours later. Antibiotic therapy was maintained, and his PSP, CRP and WBC were dosed daily. On Day 18, the three biomarkers were reported at 225 ng/ml, 157 mg/l and 12.3 G/L, respectively.

The patient reported no pain on days 19 and 20, with transient febrile episodes during the night. No issues were reported after the abdominal examination, and his CRP and WBC counts were stable. However, PSP concentrations were elevated at 392 ng/ml and >600 ng/ml on Days 19 and 20, respectively. Another abdominal CT was performed, which showed intraperitoneal fluid collections of radiological density. This suggested an intra-abdominal infection.

The patient again had surgery which confirmed intra-abdominal infection and postoperative peritonitis. An intraperitoneal lavage was performed, the abdomen was kept open, and a laparostomy using VAC with continuous intraperitoneal lavage was put into place. PSP, CRP, and WBC count decreased on days 21 and 22. The patient reported chills and a fever on day 22. His PSP doubled from 273 in the morning to 492 ng/ml later in the day. He underwent intraperitoneal lavage for intra-abdominal infection.

© For personal and private use only. Reproduction must be permitted by the copyright holder. Email to [copyright@mindbyte.eu](mailto:copyright@mindbyte.eu).

His condition improved with daily abdominal lavage. By day 26, the abdominal wall was closed. PSP levels were 330 ng/ml on day 30, corresponding to an abdominal wall infection. The patient's condition was favourable from day 30 onwards, with regular abdominal wall lavages. The patient was discharged after 47 days.

The case report illustrates the ability of PSP to function as a warning sign and allow the early identification of intra-abdominal infection and postoperative peritonitis. In this particular case, PSP facilitated prompt surgery. This demonstrates that PSP has a high diagnostic performance for identifying infection and sepsis, and serial routine PSP measurements can facilitate pre-symptomatic diagnosis of sepsis.

[Click here](#) for more Sepsis news.

Source: [Journal of Surgical Case Reports](#)

Image Credit: [iStock](#)

Published on : Thu, 24 Nov 2022