

---

## Volume 14 - Issue 4, 2014 - Management Matrix

### PET-MR: Challenges and New Directions



**[Prof. Dr. med. Mathias Goyen](#)**

Industry Adviser

\*\*\*\*\*@\*\*\*goyen.de

Professor of Diagnostic Radiology  
- Hamburg University, Germany  
Chief Medical Officer - GE  
Healthcare, Europe

[LinkedIn](#) [Twitter](#)

---

### Key Points

- The combination of PET and MR technology is highly complementary.
- The issue of accurate MR-based methods for attenuation correction of the measured PET data needs to be addressed.
- PET-MR imaging is clinically indicated for certain paediatric cancers, lymphoma, breast and prostate cancers and head and neck tumours, with the benefit of reduced radiation exposure. Future applications may include imaging the brain for Alzheimer's disease.
- Few clinical studies are published, but several show a better performance in indications requiring high soft tissue contrast.
- Use of quantitative measurements of tracer uptake is preferable to visual assessment in determining accurately and objectively the degree of tumour response.
- Factors affecting uptake include cost, reimbursement, establishing clinical benefits, caseload and case mix.

The combination of clinical MR and PET scanners has received increasing attention in recent years. The information provided by MR enables PET-MR to go far beyond simple anatomical registration of PET molecular imaging, while the simultaneous acquisition of PET and MR data opens up new opportunities impossible to realise using sequentially acquired data. This combination of MR and PET technology has proven to be very challenging due to the detrimental effect of the scanners on each other's performance. Significant progress has been made in the last 10 years to solve various technical issues, leading to the recent release of clinical whole-body hybrid scanners.

### Technical Aspects

As PET lacks the spatial resolution offered by MRI, which in turn lacks sensitivity, the combination of PET and MR technology is highly complementary. While PET-CT scanners have quickly been integrated into clinical routine, the development of combined PET and MR has been much slower, because of numerous technical challenges on both sides (Catana et al. 2013). MR cannot simply replace the CT part of a PET-CT scanner, as a whole-body PET-MR system requires technical modifications of both the PET and MR part. Details of the physics of these challenges (Quick 2014) are beyond the scope of this article. One major challenge of PET technology in an MR environment is the presence of a magnetic field causing spatial distortion in photomultiplier tubes (PMT), which are the scintillation light detectors for PET scanners. Advances in photodetector technology have led to silicon-PMTs, which are insensitive to magnetic fields.

PET, on the other hand, can be challenging for MR technology (image artefacts or decreased signal-to-noise ratio, susceptibility effects etc.). Moreover, the issue of accurate MR-based methods for attenuation correction of the measured PET data, particularly important for quantitative PET, needs to be addressed. Different methods for deriving attenuation maps from MR have been proposed (Catana et al. 2013; Pace et al. 2013). One of the main challenges, i.e. the limited space available inside the bore of standard MR systems, has been solved by introducing larger, 70 cm bore diameters providing enough space to integrate the PET camera (Catana et al. 2013).

### PET-MR Scanners for Clinical Use

Following the installation of the first head-only PET-MR scanner in 2007 (Schlemmer et al. 2008), whole-body PET-MR scanners have been introduced into clinical routine by the major medical equipment manufacturers (Siemens Healthcare, Philips Healthcare, GE Healthcare), proposing different PET-MR designs. As only a few whole-body PET-MR systems are already operating, the challenge is to understand the

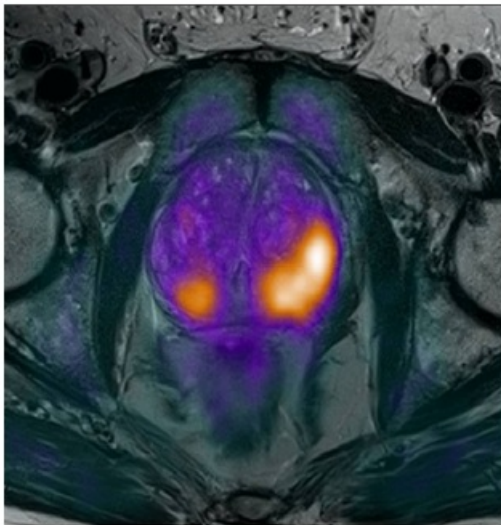
© For personal and private use only. Reproduction must be permitted by the copyright holder. Email to [copyright@mindbyte.eu](mailto:copyright@mindbyte.eu).

clinical potential of this new imaging modality. Although still limited in numbers, several studies show a better performance in those indications requiring high soft tissue contrast.

## Clinical Applications

Whole-body PET-MR imaging has the potential to supplement or even replace combined PET-CT imaging in selected clinical indications. When discussing the immediate benefits of combined PET-CT examinations, the issue of patient exposure must be taken into account. As shown in a multicentre study, whole-body PET-CT examinations result in an effective dose to patients in the order of 25 mSv, and thus mandate a thorough medical justification for each individual patient. Up to 70% of the total radiation exposure is contributed by CT (Brix et al. 2005). It would thus be very welcome if PET-MR could replace PET-CT whenever possible, as soon as the methodological challenges of this new imaging modality have been overcome.

In various paediatric malignancies PET-CT has significantly improved diagnostic accuracy. However, due to the increasing consideration of radiation risk, especially to the paediatric population, prospective studies are limited, because whenever a PET scan is needed in these patients a CT scan is also required for attenuation correction or for anatomical correlation. MR in PET-MR scanners could replace CT for attenuation correction in these patients, thereby significantly reducing radiation exposure compared to a PET-CT study (Catana et al. 2013).



**Figure 1.**  
PET-MR image of the prostate in a patient with suspected prostate cancer showing both lobes are affected (left > right). By combining PET and MR data, a more accurate delineation of prostate cancer is possible.  
Image credit: Prof. Dr. med. Thomas Lauenstein, Dept. of Radiology University Medical Center Essen/Germany

Radiation exposure is also of concern in adult patients in need for multiple PET-CT scans, such as lymphoma patients. Here PET-MR is a highly attractive alternative imaging modality, providing accurate anatomic localisation without any radiation exposure associated with CT scanning (Drzezga et al. 2012; Platzeck et al. 2012).

In patients with head and neck malignancies, MR is superior to CT in terms of accurate staging of tumour extent, involvement of soft tissue structures and nodal involvement. Therefore, PET-MR will likely improve the assessment of tumour extent, involvement of bony structures and bone marrow (Catana et al. 2013).

MR is also the modality of choice to assess and stage prostate cancer. It can reliably diagnose extracapsular extent and neural invasion (see Figure 1) and can improve the accuracy of the assessment of the primary tumour (Jambor et al. 2012; Beer et al. 2011).

In breast cancer MR has been shown to be very useful for local staging and treatment monitoring, and it has greater sensitivity even than conventional imaging methods. Currently, there is insufficient data from larger patient cohorts available regarding the performance of combined PET-MR in imaging primary breast cancer and determining local tumour extent. Initial experience with a combined PET-MR approach for the evaluation of the primary tumour suggests that adding FDG-PET information to MR mammography leads to improved information regarding local tumour extent (Buchbender et al. 2014; Pace et al. 2014).

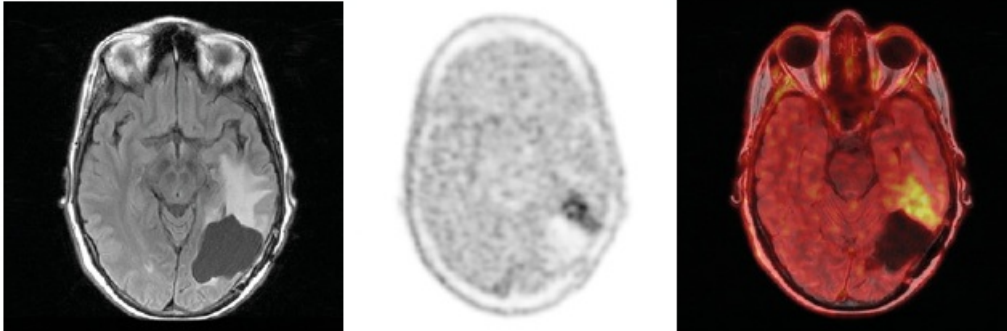
PET/CT is increasingly used for monitoring the effectiveness of therapy in patients with malignant diseases. Use of quantitative measurements of tracer uptake is preferable to use of visual assessment in determining accurately and objectively the degree of tumour response. Combined PET/MR measurements could help quantify precisely how tumour vascular properties (assessed by functional MR methods), proliferation and anti-tumour effects (assessed with PET) occur and interact (Catana et al. 2013) (see Figure 2).

A future application where PET-MR may change how we practice is to assess patients with suspected Alzheimer's disease (AD). The combination of PET and MR imaging will lead to an earlier and more definitive diagnosis as PET and MR provide complementary information

(Jack 2008): PET can characterise local uplod of amyloid, whereas MR depicts neuronal degeneration.

## Costs and Reimbursement

The applicability and recognition of PET-MR as an imaging modality in diagnostic oncology is affected by several factors, of which reimbursement seems to be a major obstacle for the diffusion of PET-MR in a clinical setting. Comparative clinical benefits for existing PET-MR approaches need to be established, as well as the caseload and case mix required for effective utilisation of a hybrid PET-MR-scanner. PET-MR has developed and matured over the last decade. The technology's cost remains a significant obstacle. Integrated PET-MR scanners carry a price tag of approximately US \$7 million. Similar to PET-CT scanners, which were very expensive when they first came out, and dropped in price as the technology became more available, PET-MR-scanners will also decline in price. More research is needed to determine the cost effectiveness of PET-MR technology (Goyen 2014).



**Figure 2.**  
PET-MR image (18F-FET, tyrosine) in a patient with known glioblastoma (GBM) (a: axial FLAIR, b: PET only, c: PET-MR) showing recurrence of GBM with FET-uptake

Image credit: Priv.-Doz. Dr. med. Patrick Veit-Halbach, Dept. Medical Radiology, University Hospital Zürich, Zürich/Switzerland)

## Conclusion

PET-MR is an exciting imaging technology with great potential, paving the way for increased diagnostic power in several clinical scenarios, but the main indication for PET-MR in oncology remains to be defined. PET-MR definitely has the potential to significantly increase our knowledge in vivo of cancer physiology. Many factors will decide the ultimate role of PET-MR systems within the overall healthcare system, not the least of which is the cost of such systems, and the degree to which the benefits accrued match the resources required to perform and interpret these studies in the clinic, as PET-MR will demand interdisciplinary training and a truly multidisciplinary set up involving physicians, physicists and technologist from both the field of nuclear medicine and PET as well as MR imaging and radiation therapy (Catana et al. 2013). If the future of clinical practice is precision medicine, where therapeutic decisions are designed around specific molecular pathological events at the earliest possible stage (Goyen 2014), then PET-MR systems will dramatically impact the expanding field of molecular imaging in the future.

Published on : Sat, 8 Nov 2014