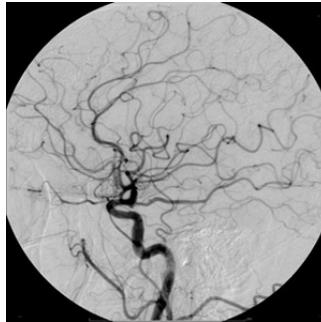

OCT Improves Post-PCI Outcome Compared to Angiography



A randomised study has revealed that optical coherence tomography (OCT) optimises the results of percutaneous coronary intervention (PCI) in patients with non-ST-segment elevation acute coronary syndromes and contributes to a better post-procedural outcome than angiography.

Angiography is the established imaging technique routinely used during PCI. However, intravascular imaging techniques offer a better evaluation of the characteristics of lesions than angiography and thus help ensure an optimal post-procedural outcome. More specifically, OCT has been shown to identify plaque morphologies associated with poorer prognosis. However, there are no randomised studies investigating the value of OCT in optimising the results of PCI in patients with non-ST-segment elevation acute coronary syndromes.

Researchers from various institutions in France collaboratively carried out a multicentre, randomised study involving 240 patients with non-ST-segment elevation acute coronary syndromes. Their primary aim was to compare OCT-guided PCI to angiography-guided PCI in terms of functional result by measuring the post-PCI fractional flow reserve (FFR).

The findings of the study revealed that OCT led to a change in the procedural strategy in 50% of the patients in the OCT-guided group. Importantly, the primary endpoint was improved in the OCT-guided group with a significantly higher FFR value in the OCT-guided group compared to the angiography-guided group (0.94 ± 0.04 versus 0.92 ± 0.05 , $P=0.005$). Moreover, there was no significant difference in the rate of type 4a myocardial infarction between groups, while the rates of procedural complications and acute kidney injury were identical despite longer procedural and fluoroscopy time in the OCT-guided group.

Post-PCI OCT revealed stent underexpansion, stent malapposition in 32%, incomplete lesion coverage in 20%, and edge dissection in 37.5%. This led to the more frequent use of post-stent overdilation in the OCT-guided group. The guidelines for the procedural strategy involved the following: length and diameter of the stent according to quantitative measures of reference vessel diameter and lesion length, additional balloon overdilation, additional stent implantation, and potential use of GP IIb/IIIa inhibitors, aspiration thrombectomy and rotational atherectomy.

Source : [Circulation](#)

Published on : Tue, 4 Oct 2016