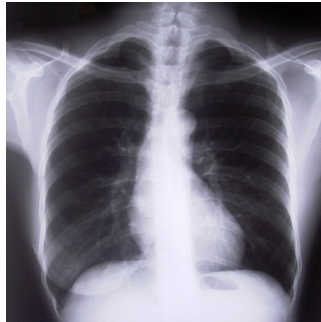


---

## NSNs in Lung Cancer Can Be Managed With Annual CT Scan



---

New research seems to support findings that lung cancers that appear as non-solid nodules (NSNs) have a slow-moving course and can be managed with annual follow-up.

The study, published in the journal *Radiology*, suggests that whereas some of these NSNs may become aggressive lung cancers over time, the changes in the nodule appearance can be documented with annual low-dose CT scans, which at present remain the best biomarker for cancer progression, especially among smokers.

NSNs are usually asymptomatic growths in the lung deriving from the fact that the normal lung tissue is visible through the nodule on a CT image. Surgical removal is a treatment option, even though NSNs are rarely life-threatening.

“When you biopsy a nonsolid nodule, it’s usually pre-malignant, noninvasive, or due to some other cause like infection or fibrosis,” said study co-author Claudia I. Henschke, M.D., Ph.D., from the Department of Radiology at Icahn School of Medicine at Mount Sinai in New York City.

In an early study published in *Radiology*, Dr. Henschke and colleagues analysed data from more than 57,000 participants in the International Early Lung Cancer Program (I-ELCAP), a worldwide initiative aimed at reducing deaths from lung cancer. They concluded that NSNs of any size could be followed with annual repeat CT scans, as any cancers found were at a very early stage and deaths among the study group were not due to those cancers.

For the new study, the researchers monitored data from the National Lung Screening Trial (NLST), a large trial that compared low-dose CT with chest X-ray for lung cancer detection. They searched the NLST database to identify all participants who had at least one NSN on a CT scan and subsequently died of lung cancer.

Among the 26,722 participants, 2,534, or 9.4 percent, had one or more NSNs. Of those, 48 died of lung cancer. Twenty-one of the 48 had no NSN in the cancerous lobe of the lung. A review of the remaining 27 cases found that death was unlikely to be caused by the NSN, as long as annual follow-up was done.

Study lead author Rowena Yip, M.P.H., senior biostatistician at Icahn School of Medicine at Mount Sinai, concluded that the causes of death in this group were likely due to another solid or part-solid nodule in the same lobe of the lung.

The new findings, along with previous research, could help spare patients from the costs, complications and stress of unnecessary biopsy and surgery.

Story Source: Radiological Society of North America ( [RSNA](#) )

### Journal Reference:

1. Rowena Yip, David F. Yankelevitz, Minxia Hu, Kunwei Li, Dong Ming Xu, Artit Jirapatnakul, Claudia I. Henschke. **Lung Cancer Deaths in the National Lung Screening Trial Attributed to Nonsolid Nodules.** *Radiology*, July 2016 DOI: [10.1148/radiol.2016152333](https://doi.org/10.1148/radiol.2016152333)

*Photo credit:* Freeimages.com/Adam Ciesielski

Published on : Tue, 12 Jul 2016