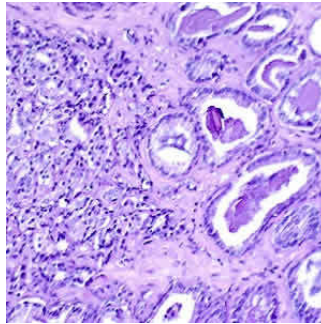

Normal and Malignant Prostates on MRI: Shape Differences



Researchers using computational imaging have identified shape differences between normal and malignant prostates on T2-weighted (T2w) MRI, according to a report published in the journal Scientific Reports. Their findings could provide quantitative measures to facilitate diagnosis or outcome prediction.

See Also: [MRI Improves Prostate Cancer Detection, Avoids Unneeded Biopsy](#)

Multi-parametric magnetic resonance imaging (MRI) plays an essential role in the management of prostate cancer (PCa), improving localisation and local staging of the disease. In addition to providing structural and functional images of the prostate, prostate MRI has also revealed differences in cancers based on their localisation in the anatomic subregions of the prostate.

The researchers sought to characterise differences in the shape of the prostate and the central gland (combined central and transitional zones) between men with biopsy confirmed prostate cancer and men who were identified as not having prostate cancer either on account of a negative biopsy or had pelvic imaging done for a non-prostate malignancy.

T2w MRI from 70 men were acquired at three institutions for use in the study. The PCa positive group (PCa+) comprised 35 biopsy positive (Bx+) subjects from all the institutions. The prostate cancer negative (PCa-) included 24 biopsy negative (Bx-) subjects from two institutions and 11 prostates from subjects suspicious for rectal cancer (and hence had a pelvic imaging scan done), without clinical indication (CI-) of PCa at the third institution.

The boundaries of the prostate and central gland (CG) were delineated on T2w MRI by two expert raters and were used to construct statistical shape atlases for the PCa+, Bx- and CI- prostates. An atlas comparison was performed via per-voxel statistical tests to localise shape differences (significance assessed at $p < 0.05$). The atlas comparison revealed central gland hypertrophy in the Bx- subpopulation, resulting in significant volume and posterior side shape differences relative to PCa+ group. Significant differences in the corresponding prostate shapes were noted at the apex when comparing the CI- and PCa+ prostates.

"Shape differences between cancer positive (PCa+) and cancer negative (PCa-) men may be the result of cancer localised in the peripheral zone. Moreover, shape differences were observed on the posterior side of the CG. The inter-rater variability may indeed have affected the CG shape, but we believe that this contribution to shape differences between the populations was a small part of the true anatomic differences manifest between PCa+ and CI- subjects," write Mirabela Rusu, PhD, of the Department of Biomedical Engineering, Case Western Reserve University, Cleveland, Ohio and co-authors.

The authors have noted several limitations of the study, including the fact that this was a preliminary study comprising a relatively small number of subjects. Also, the comparison of prostate shapes between subpopulations is a difficult task on account of various factors. For instance, the prostate shape varies naturally and changes with age as the volume of the prostate increases. The atlas comparison framework was designed to correct the natural variability and allow the comparison of shapes.

Source: [Scientific Reports](#)

Image Credit: [Otis Brawley](#)

Published on : Tue, 14 Feb 2017