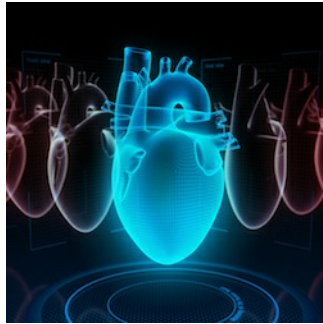




New power of diagnostic imaging: PET/MRI predicts cardiovascular inflammation in arteries



Using advanced PET/MRI technology, researchers at the CNIC have detected arterial inflammation in regions that have yet to develop atherosclerotic plaques

Using advanced **PET/MRI** technology, researchers at the [Centro Nacional de Investigaciones Cardiovasculares](#) (CNIC) have **detected arterial inflammation** in **regions that have yet to develop atherosclerotic plaques**. Results of the PESA-CNIC-Santander study published in the [Journal of the American College of Cardiology](#) (JACC); the research team used this **innovative technology** to analyse the inflammatory process in the arteries of a group of people who had already developed atherosclerotic plaques.

The study examined the largest cohort examined by **PET/MRI** to date. In the results of this study it is evident, for the first time, that inflammation is present at early stages of atherosclerosis, especially all in regions that have not developed plaques. The study also reports that this arterial atherosclerosis can be an early indication of the later appearance of plaques that underlie **cardiovascular disease** and events such as **heart attack** and stroke. The researchers state they are currently analysing the role of arterial inflammation in this process, as this information will help them establish early diagnosis and develop new anti-inflammatory therapies for the disease.

Although atherosclerosis is known to be a **chronic inflammatory disease**, the prevalence and distribution of inflammation at early disease stages was not definitively known. PESA-CNIC-Santander is a prospective study led by [Dr. Valentín Fuster](#) that utilised **innovative imaging technologies** to analyse more than **4000 middle-aged participants** and evaluate the presence and development of **atherosclerosis** at subclinical stages--**before symptoms appear**.

The results published were derived using advanced PET/MRI technology in **755 asymptomatic** participants in the PESA-CNIC-Santander study. The average of the participants was **49 years** of age, and they all had atherosclerotic plaques detected by **2D/3D ultrasound** or accumulation of calcium in the arteries.

Vascular inflammation

[Leticia Fernández-Friera](#), study co-author and a cardiologist at the CNIC and HM Montepíncipe University Hospital, stated the main goal of the study "was to characterise vascular inflammation in people with known subclinical atherosclerosis by examining three territories: the carotid arteries, which supply blood to the head; the aorta, the body's largest artery; and the **iliofemoral** arteries, which supply blood to the legs."

Dr. Valentín Fuster, CNIC Director and lead investigator on the project, emphasised **the power of modern diagnostic imaging technology**, which "has revealed that inflammation is present in only 10% of established plaques." [Javier Sanz](#), co-author of the study explained, "the atherosclerotic plaques showing signs of inflammation are large, have a high cholesterol content, and tend to be located in the femoral arteries at the arterial bifurcations." Nevertheless, he said "most inflammation identified in the arteries of this PESA study subpopulation are located in vessel regions free of atherosclerotic plaques."

Risk factors

Sanz further explained that the study data show inflammation in the arteries of "almost half of the participants, occurring more frequently in the femoral arteries." Fernández-Friera added, "inflammation was associated with the presence of more risk factors; obesity and smoking in particular were independent predictors of the presence of arterial inflammation."

Dr. Fuster emphasised that these **findings demonstrate the power of this technology to produce live images** of inflammation related to systemic atherosclerosis, thus enabling the study of this disease in early stages and the identification of individuals likely to benefit from early medical intervention. "Future studies should investigate whether inflammation precedes the development of the plaque and assess how the quantification of inflammation might contribute to the evaluation of cardiovascular risk."

Source: [Journal of the American College of Cardiology](#)

Image Credit: iStock

Published on : Tue, 26 Mar 2019