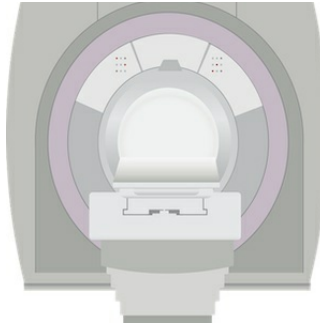

MRI in Pulmonary Embolism Diagnosis



Magnetic resonance imaging (MRI) has high specificity but limited sensitivity for the diagnosis of pulmonary embolism (PE), according to a systematic review published in the journal *Thrombosis Research*. Given these inconclusive results, researchers say management studies are needed to more precisely define the role of MRI in the diagnostic workup of patients with suspected PE.

Pulmonary embolism is the third leading cause of cardiovascular deaths. Because of the associated risk of severe bleeding complications, an accurate diagnosis is necessary before starting anticoagulant treatment. Computed tomographic pulmonary angiography (CTPA) has simplified the diagnostic approach to patients with clinically suspected PE.

The increased use of CTPA in the emergency departments, however, has raised some concerns: many patients at low pre-test probability of PE are inappropriately exposed to radiation and contrast medium, and many others are probably inappropriately treated for small, subsegmental emboli. Alternative diagnostic strategies have been advocated to overcome these limitations.

Alessandro Squizzato, MD, Department of Medicine and Surgery, University of Insubria, Varese, Italy and colleagues performed a systematic review and meta-analysis of the literature to better assess the accuracy of MRI for the diagnosis of PE. Relevant studies were systematically searched in the PubMed and EMBASE databases (up to May 2016). A bivariate random-effects regression approach was used for summary estimates of both sensitivity and specificity.

Thirteen studies, for a total of 1170 patients, were included in the analysis. Weighted mean prevalence of PE was 37% at random-effect model. Weighted mean inconclusive MRI results were 19% at random-effect model. After exclusion of inconclusive results, MRI was positive in 297 of 374 patients with objectively confirmed PE (bivariate weighted mean sensitivity 80.9%; 95% confidence interval [CI] 68.2, 89.4%), whereas MRI was normal in 599 of 620 patients in whom PE was objectively ruled out (bivariate weighted mean specificity 96.4%; 95% CI 92.4, 98.3%).

MRI has several potential strengths that suggest it may be a useful alternative to CTPA, according to the review team. For instance, the high sensitivity for proximal emboli may be relevant for excluding PE in some patient subgroups, such as nonpregnant women of childbearing age. Moreover, the high overall specificity makes MRI suitable to demonstrate PE in patients with a high clinical suspicion of PE.

"Although at present the MRI is not yet ready for immediate clinical use, it may become a useful diagnostic tool in the management of patients with suspected PE, such as excluding PE when CTPA is contraindicated or not available. Ongoing and future management studies will conclusively ascertain the actual role of MRI in the diagnostic workup of patients with suspected PE and, hopefully, improvement in MRI technology will improve its diagnostic capabilities," the authors conclude.

Source: [Thrombosis Research](#)

Image credit: [Pixabay](#)

Published on : Tue, 25 Apr 2017