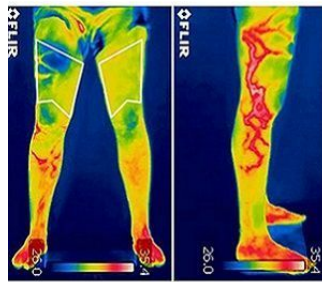


## Infrared Thermography Offers Faster Diagnosis of Orthopaedic Injuries



Researchers in Spain have confirmed the effectiveness of infrared thermography for detection and early diagnosis of orthopaedic injuries, according to a study published in the *Journal of Medical Imaging and Health Informatics*. Results show that this technology is a great support tool to correctly identify the presence or absence of injuries in a particular body part.

Currently, different methods are used for reliable diagnosis of orthopaedic injuries: x-rays and scanners for bone injuries, ultrasound scans for muscle injuries, and MRIs for meniscus and ligament injuries. However, thermography allows a reliable, faster and low-cost detection of these injuries based on the measurement of skin temperature at different body parts. By using an infrared camera, an image can be obtained in which every colour represents a different temperature. Thus, considering that skin temperatures of contralateral regions are symmetrically distributed in a healthy person, a thermal asymmetry in different areas can help detect or even prevent some type of injury.

The study was conducted by a research group of Thermography Unit from the Faculty of Sciences for Physical Activity and Sport (INEF) at Universidad Politécnica de Madrid (UPM). The research was carried out with patients of the Emergency Unit of Clínica CEMTRO to establish the capacity of infrared thermography (IRT) to discriminate injuries and to evaluate its applicability in emergency trauma scenarios.

The results show significant differences of skin temperatures among regions of interest injured and uninjured, for both average temperature values and maximum values. These values are distributed according to the injured region of interest, the type of injury, the diagnosis and the progress of the injury and they show that skin temperature has a good specificity for the detection of temperature asymmetries in areas injured, and therefore this method can be considered as a reference to make decisions on the existence of an orthopaedic injury.

In addition, the study assessed the influence of the use of ice and anti-inflammatory drugs taking into account some of the cases excluded of the general study in order to conduct a specific analysis of the effects of anti-inflammatory remedies.

The findings show that, when a high-resolution thermographic camera is used and an appropriate protocol is followed, IRT is a suitable support tool to provide practitioners with additional data to correctly identify the presence or absence of an injury, the authors conclude.

**Top image** - Left: Data collection of the injured and uninjured regions of interest (right quadriceps with moderate muscle strain). Right: Lateral picture of the same person in which we see a possible vascular problem, this provides additional information that would be impossible to perceive at first glance.

Source and image credit: [Universidad Politécnica de Madrid](#)

Published on : Fri, 4 Dec 2015