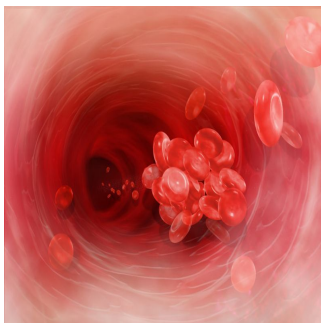


## Imaging Acute Ischemic Stroke Patients' Brains Did Not Lead to Improved Outcomes



The use of advanced imaging shortly after the onset of acute stroke failed to identify a subgroup of patients who could benefit from a clot-removal procedure, a study has found.

The randomized controlled trial known as Mechanical Retrieval and Recanalization of Stroke Clots Using Embolectomy (MR RESCUE) was funded by the National Institute of Neurological Disorders and Stroke (NINDS), part of the National Institutes of Health, and was published online Feb. 8 in the New England Journal of Medicine.

In patients with ischemic stroke (caused by a blockage in an artery), brain cells deprived of blood die within minutes to hours. Rapidly opening the artery can halt brain cell death. Intravenous tissue plasminogen activator (t-PA), a drug that dissolves clots has been shown to improve outcomes in such stroke patients. However intravenous t-PA is not effective in many patients with large clots blocking the major brain arteries that cause the most devastating strokes. MR RESCUE investigators tested an invasive clot removal strategy designed to remove clots from these large arteries. Patients in the study were enrolled at 22 centers in the United States within approximately 5.5 hours of their stroke onset. Their ability to function independently was assessed at 90 days.

All MR-RESCUE patients underwent emergency computed tomography (CT) or magnetic resonance (MRI) perfusion imaging to identify regions of the brain with decreased blood flow, as well as regions that could not be salvaged.

The investigators hypothesized that patients in whom the scan suggested that less than 70 percent of the brain with decreased blood flow had already died would benefit from the clot-removal procedures. Based on the imaging results, the 118 study patients were randomly assigned to receive a clot-removal procedure within eight hours of symptom onset (64 patients) or standard therapy (54 patients) according to medical protocols. The procedure involves threading a special catheter through an artery in the groin up to the site of a clot in a brain artery, then removing the blockage.

"Despite a lack of evidence showing that these clot-removal devices improve outcomes, they are already widely used in patients who are not able to get to the hospital in time to receive t-PA," said Walter J. Koroshetz, M.D., deputy director of NINDS. "Though some patients have had dramatic improvements with clot removal, it has not been shown effective in this or another larger study, the Interventional Management of Stroke (IMS III), which was halted early because it did not find the procedure to be of significant benefit."

"The majority of patients were not eligible to receive intravenous t-PA, the only drug approved by the Food and Drug Administration for the treatment of stroke, because they arrived at the hospital too late for t-PA to be effective," said one of the primary investigators, Chelsea Kidwell, M.D., of Georgetown University Medical Center in Washington, D.C. As brain cells are dying continuously in the minutes and hours after stroke, the earlier that treatment is given the greater the likelihood of a good outcome for the patient.

The patients with the presumed favorable imaging findings had the same level of disability at 90 days whether or not they had undergone the clot-removal procedure or had received standard therapy. The researchers hypothesized that the lack of a treatment effect may reflect the fact that these patients had enough blood flow to the brain from secondary sources to support the brain tissue until spontaneous reperfusion occurred. Patients without the favorable imaging findings did not benefit from the clot-removal procedure.

However, the results of MR RESCUE are not consistent with the conclusions of a separate NINDS-funded observational study called [DEFUSE-2](#) that suggested that a slightly different brain imaging strategy could predict patients who benefited from the clot-removal procedure.

In addition to other imaging techniques "it's possible that newer intra-arterial devices that were not available when the study started could improve functional outcomes," said Scott Janis, Ph.D., program director, NINDS. "But an important message from MR RESCUE is that those newer devices still need to go head to head with standard therapy."

"Advances in neuroimaging are promising and may someday help to identify who will benefit from a device-based approach. But the MR RESCUE results show that more work needs to be done," Dr. Koroshetz said.

#### References:

- Kidwell C, Jahan R, Gornbein J, *et al.* "A trial of imaging selection and endovascular treatment for ischemic stroke intervention," N. Engl. J. Med. 2013. DOI: 10.1056/NEJMoa1212793.
- NINDS (<http://www.ninds.nih.gov>) is the nation's leading funder of research on the brain and nervous system. The NINDS mission is to reduce the burden of neurological disease – a burden borne by every age group, by every segment of society, by people all over the world.

Published on : Sat, 9 Mar 2013