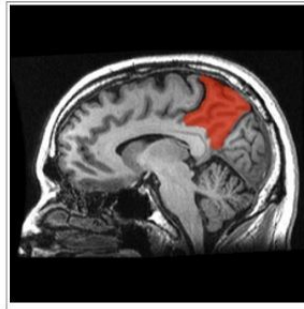

Happiness in an MRI



Happiness is a subjective experience; for instance, some people feel happiness more intensely than others when they receive compliments. To better understand the neural mechanism behind how happiness emerges, researchers in Japan conducted a study using MRI brain scans. Overall happiness, according to the study, is a combination of happy emotions and satisfaction of life coming together in the precuneus, a region in the medial parietal lobe that becomes active when experiencing consciousness.

The findings are reported in the journal *Scientific Reports*. For the study, Wataru Sato and his team at Kyoto University scanned the brains of research participants with magnetic resonance imaging (MRI). The participants then took a survey that asked how happy they are generally, how intensely they feel emotions, and how satisfied they are with their lives.

Their analysis revealed that those who scored higher on the happiness surveys had more grey matter mass in the precuneus. In other words, people who feel happiness more intensely, feel sadness less intensely, and are more able to find meaning in life have a larger precuneus.

Previous functional neuroimaging studies have shown that the precuneus region has the highest level of cortical glucose metabolism in the brain, highlighting the importance of this region for subjective consciousness in humans. In addition, the precuneus is involved in "self-referential" processing, which integrates the information of one's current internal experience, past memory, and future plans.

"Over history, many eminent scholars like Aristotle have contemplated what happiness is," says lead author Wataru Sato. "I'm very happy that we now know more about what it means to be happy."

Sato is hopeful about the implications this study has for happiness training.

"Several studies have shown that meditation increases grey matter mass in the precuneus. This new insight on where happiness happens in the brain will be useful for developing happiness programmes based on scientific research," he explains.




Figure 1: Brain region significantly associated with the subjective happiness score.

(Left) A statistical parametric map ($p < 0.001$, peak-level uncorrected for display purposes). The area is overlaid on the spatially normalised grey matter tissue probability map. The blue cross indicates the location of the peak voxel. The red-white colour scale indicates the T-value. (Right) A scatter plot of the adjusted grey matter volume as a function of the subjective happiness score at the peak voxel.

Source: [Kyoto University](#)

Image credit: Scientific Reports; TheFreeDictionary.com

Published on : Thu, 26 Nov 2015