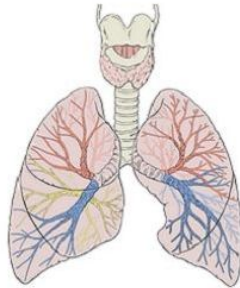


CT Screening for Lung Cancer



A new study published in *Radiology* shows that annual low-dose computed tomography (CT) screening can be effective in monitoring people with nonsolid lung nodules. Researchers say the findings could help spare patients from unnecessary surgery and additional imaging.

"Nonsolid nodules could be due to inflammation, infection or fibrosis, but could also be cancerous or a precursor of cancer," explains study co-author Claudia I. Henschke, PhD, MD, from the Department of Radiology at Mount Sinai School of Medicine in New York City. "For screening, we have to define which nodules need further workup and how quickly we have to do that workup."

Lung nodules are classified as solid, part solid or nonsolid, based on their appearance on CT. In nonsolid lung nodules, normal lung tissue is visible through the nodule. Nonsolid nodules are visible on CT scans of the chest, and management of them is challenging.

For this study, the researchers analysed results from 57,496 participants in the International Early Lung Cancer Programme (I-ELCAP), which aims to reduce deaths from lung cancer. The patients underwent baseline and annual repeat screenings, and the researchers assessed the prevalence of nonsolid nodules and their effect on long-term outcomes. Dr. Henschke's team reported these findings:

- A nonsolid nodule was identified in 2,392 (4.2 percent) of the baseline screenings, and further analysis led to the diagnosis of 73 cases of cancer.
- A new nonsolid nodule was identified in 485 of 64,677 annual repeat screenings, or 0.7 percent, and 11 were diagnosed with Stage I cancer.
- Surgery was 100 percent curative in all cases, with a median follow-up since diagnosis of more than six years.

In addition, the nonsolid nodule developed a solid component — a warning sign of invasive cancer — in 22 cases prior to treatment. However, the median transition time from nonsolid to part-solid was more than two years. No cancers occurred in new nodules 15 millimetres or larger in diameter.

Based on the results, "if we see a nonsolid lung nodule of any size, we can tell people to come back in one year for another CT," says Dr. Henschke. "These findings are important for reducing unnecessary CT scans and possible biopsies or surgery in programmes of CT screening for lung cancer."

The research team hopes the study will be helpful in reducing overtreatment of nodules. "Many recommendations had been fairly aggressive with respect to nonsolid nodules," notes study co-author David F. Yankelevitz, MD, from Mount Sinai. "These results show that there is no reason to be aggressive in pursuit of cancer, so long as the nodules stay in this nonsolid form."




Figure 1. CT images in a 68-year-old smoker show (a) a nonsolid nodule (17 x 13 x 13 mm) in the left upper lobe at baseline screening, (b) the nodule remained nonsolid at follow-up 2 years later, and (c) a solid component emerged at follow-up 9 years later. At that time, it was resected, and the final diagnosis was 2.1-cm invasive adenocarcinoma.

□

Figure 2. Graph shows the likelihood of diagnosing a lung cancer manifesting in a nonsolid nodule, separately in the baseline (blue) and annual repeat (red) rounds of CT screening.

Source: [RSNA](#)

Image credit: RSNA, Wikimedia Commons

Published on : Tue, 23 Jun 2015