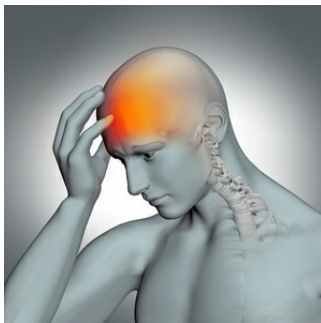


---

## Concussion-Related Injury Detected in the Living Brain



---

A collaborative study among institutions in the United States published in *Translational Psychiatry* by Dickstein and colleagues has revealed that an experimental positron emission tomography (PET) tracer can now diagnose a concussion-related neurodegenerative disorder while a patient is still alive.

The association between repetitive traumatic brain injury (TBI) and long-term effects on general health has recently gained great attention, as it has been severely affecting athletes and soldiers with a history of multiple concussions manifesting progressive neuropsychiatric symptoms. Until now, the diagnosis of chronic traumatic encephalopathy (CTE) could only be established after the death of an individual. A new PET ligand can now provide an antemortem detection of tau aggregates associated with the disorder.

An experimental imaging agent called [18 F]-T807, or Avid 1451, with PET was used to examine the brain of a 39-year-old retired National Football League player who had suffered 22 concussions and manifested progressive neuropsychiatric symptoms. The main symptoms reported by the patient were emotional lability and irritability.

Neuropsychological exams showed a decline in executive functioning, processing speed and fine motor skills. Magnetic resonance imaging (MRI) scans revealed cortical thinning in the left frontal and lateral temporal areas and volume loss in the basal ganglia.

The National Institute of Neurological Disorders and Stroke (NINDS) has described the diagnostic criteria for CTE based on post-mortem brain tissue samples. Its manifestation includes wrinkles and folds on the surface of the brain and tau accumulation at the deepest points of the highly folded surfaces. These are considered pathognomonic, which means that CTE is considered to be present beyond any doubt. The scan of the current study's participant is the first to reveal a pattern of tau imaging that outlines the aforementioned wrinkles and folds in the brain of a living individual.

The case study provides “a window into the neuropsychiatric and structural progression of CTE” and suggests that tauopathy imaging is a promising to detect concussion-related neuropathology in living patients. Further research will demonstrate in what cases tauopathy imaging can be applied to identify and track the progression of CTE-related neurodegeneration.

**Source :** [Translational Psychiatry](#)

Published on : Mon, 10 Oct 2016