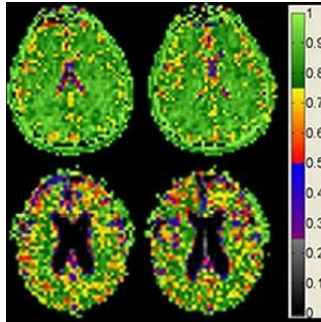


Cell Density Unchanged as Brain Shrinks With Age



Using a powerful 9.4-Tesla MRI — the first of its kind for human imaging — researchers at the University of Illinois at Chicago have obtained the most detailed MRI images of the brain so far to show that while the brain shrinks with age, brain cell density remains constant. The findings are reported in the journal *NMR in Biomedicine*.

The 9.4-Tesla images provide the first evidence that in normal ageing, cell density is preserved throughout the brain, not just in specific regions, as previous studies on human brain tissue have shown. The new findings also suggest that the maintenance of brain cell density may protect against cognitive impairment as the brain gradually shrinks in normal ageing.

"The information provided by these 9.4-Tesla scans may be very useful in helping us to detect tiny losses of brain cells and the reduction in cell density that characterises the early stages of neurodegenerative diseases that can take decades to develop before symptoms appear, like Alzheimer's disease," says lead author Dr. Keith Thulborn, director of MRI research in the UIC College of Medicine.

"If we can identify when Alzheimer's pathology starts, the efficacy of new drugs or other interventions to slow or prevent Alzheimer's disease can be tested and monitored when the disease starts, instead of after it's developed for 20 or 30 years and becomes clinically apparent," explains Dr. Thulborn, who is professor of radiology, physiology and biophysics.

For this study, Dr. Thulborn and his team scanned the brains of 49 cognitively normal adults ranging in age from 21 to 80. All had at least a college education and were employed or, if retired, were active in their communities. All subjects were without major medical, neurological or psychiatric disease and scored within the normal range for mental status.

The 9.4 Tesla MRI measures sodium ions, which are present throughout the body and are pumped in and out of neurons to generate the electric potentials needed to spark nerve impulses. Sodium concentrations in the brain reflect neuron density. Areas of low sodium concentration indicate lots of neurons packed tightly together, while higher sodium concentration can indicate more space between cells — or the loss of cells, as in the case of neurodegenerative diseases.

The 9.4 T magnetic field is more than three times stronger than that of a conventional MRI machine and is currently approved only for research. The strongest MRI units approved for clinical use are 3 T.

Dr. Thulborn thinks the ultra-high-field scanners eventually will be approved for clinical use. As he points out: "We can use the 9.4 T to look at brain cell loss in real time in patients experiencing stroke, or to see whether chemotherapy for brain tumours is working in higher resolution that is just not available using the current 3 T clinical scanners."

Source: [University of Illinois at Chicago](#)

Image credit: Dr. Keith Thulborn, UIC

Published on : Tue, 16 Jun 2015